

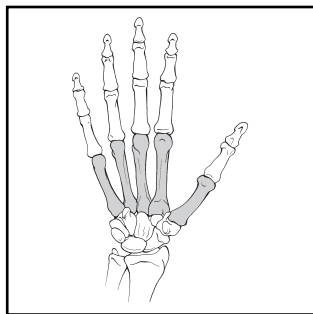
METACARPALS

BONE: METACARPALS (77)

Modifiers for metacarpals:

T, thumb; I, index; M, middle; R, ring; L, little.

Location: Metacarpals (77)



Types:

A. Metacarpal proximal and distal nonarticular and diaphysis non-comminuted (77-A)

B. Metacarpal proximal and distal partial articular diaphysis wedge comminution (77-B)

C. Metacarpal proximal and distal complete articular diaphysis comminuted (77-C)

Groups:

1. Metacarpal, proximal extra-articular (77-A1)

2. Metacarpal, diaphysis non-comminuted (77-A2)

3. Metacarpal, distal extra-articular (77-A3)

1. Metacarpal, proximal partial articular (77-B1)

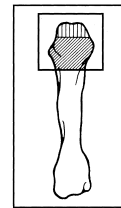
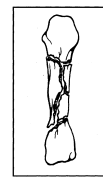
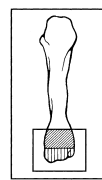
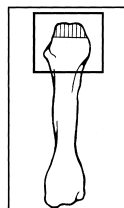
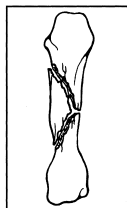
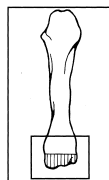
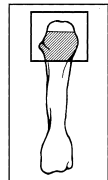
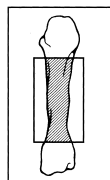
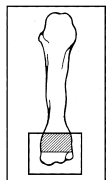
2. Metacarpal, diaphysis wedge (77-B2)

3. Metacarpal, distal partial articular (77-B3)

1. Metacarpal, proximal complete articular (77-C1)

2. Metacarpal, diaphysis comminuted (77-C2)

3. Metacarpal, distal complete articular (77-C3)



Subgroups and Qualifications:

Metacarpal, proximal extra-articular (77-A1)

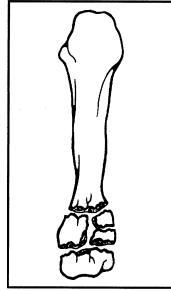
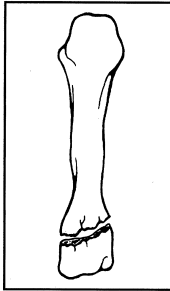
1. Noncomminuted (77-A1.1)

2. Comminuted (77-A1.2)

(1) wedge

(2) complex

A1



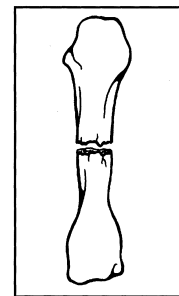
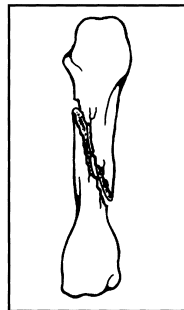
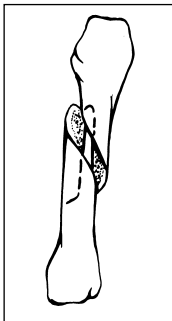
Metacarpal, diaphysis noncomminuted (77-A2)

1. Spiral (77-A2.1)

2. Oblique (77-A2.2)

3. Transverse (77-A2.3)

A2

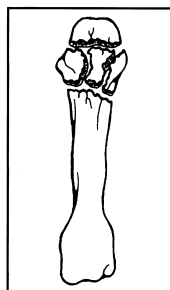
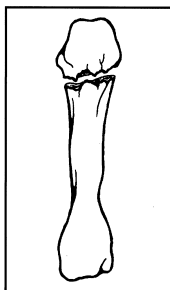


Metacarpal, distal extra-articular (77-A3)

1. Noncomminuted (77-A3.1)

2. Comminuted (77-A3.2)

A3



Metacarpal, proximal partial articular (77-B1)

1. Avulsion OR Split (77-B1.1)

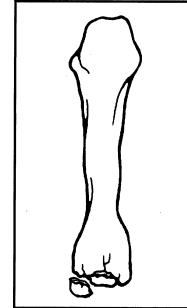
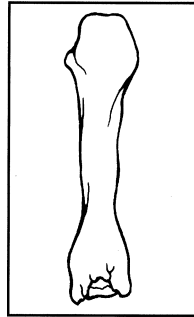
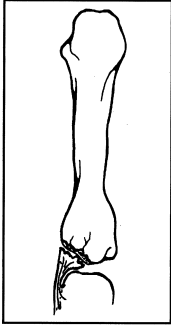
- (1) unicondyle medial
- (2) unicondyle lateral
- (3) coronal split volar fragment
- (4) coronal split dorsal fragment

2. Depression (77-B1.2)

3. Split/depression (77-B1.3)

- (1) unicondyle medial
- (2) unicondyle lateral
- (3) coronal split volar fragment
- (4) coronal split dorsal fragment

B1



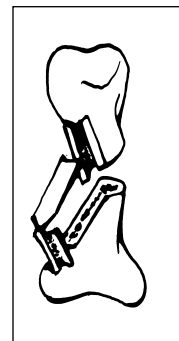
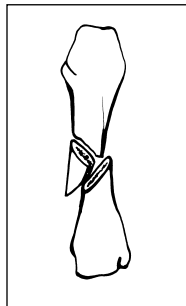
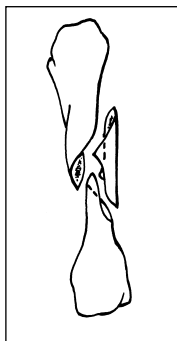
Metacarpal, diaphysis wedge (77-B2)

1. Spiral (77-B2.1)

2. Bending (77-B2.2)

3. Comminuted (77-B2.3)

B2



Metacarpal, distal partial articular (77-B3)

1. Avulsion OR Split (77-B3.1)

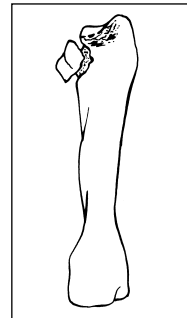
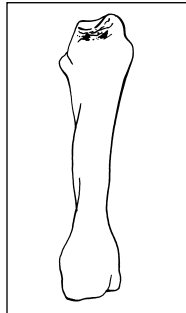
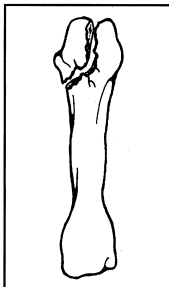
- (1) unicondyle medial
- (2) unicondyle lateral
- (3) coronal split volar fragment
- (4) coronal split dorsal fragment

2. Depression (77-B3.2)

3. Split/depression (77-B3.3)

- (1) unicondyle medial
- (2) unicondyle lateral
- (3) coronal split volar fragment
- (4) coronal split dorsal fragment

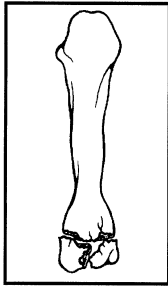
B3



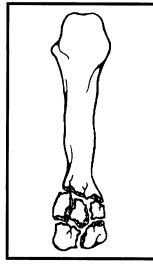
Metacarpal, proximal articular (77-C1)

1. Noncomminuted articular and metaphysis (77-C1.1)

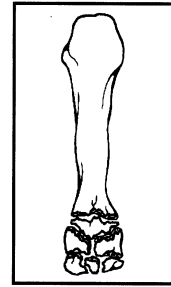
C1



2. Noncomminuted articular, comminuted metaphysis (77-C1.2)



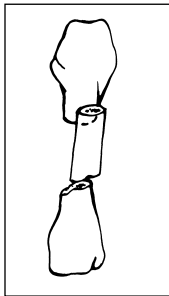
3. Comminuted articular (77-C1.3)



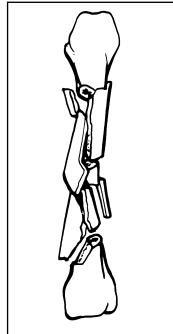
Metacarpal, diaphysis comminuted (77-C2)

1. Segmental (77-C2.1)

C2



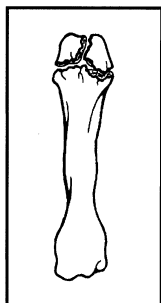
2. Complex comminuted (77-C2.2)



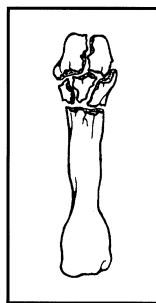
Metacarpal, distal articular (77-C3)

1. Simple articular/metaphysis (77-C3.1)

C3



2. Simple articular/comminuted metaphysis (77-C3.2)



3. Comminuted articular (77-C3.3)

